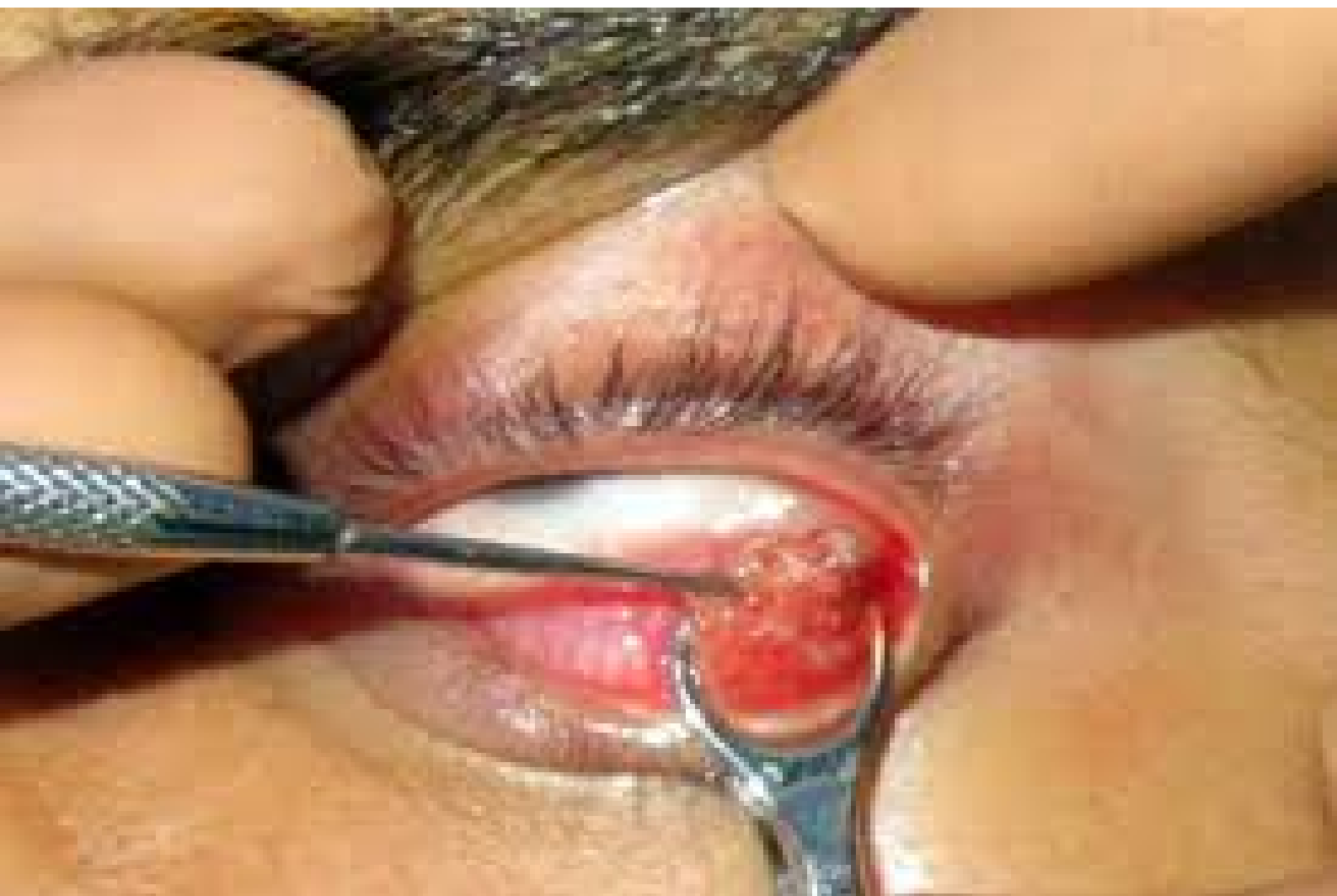
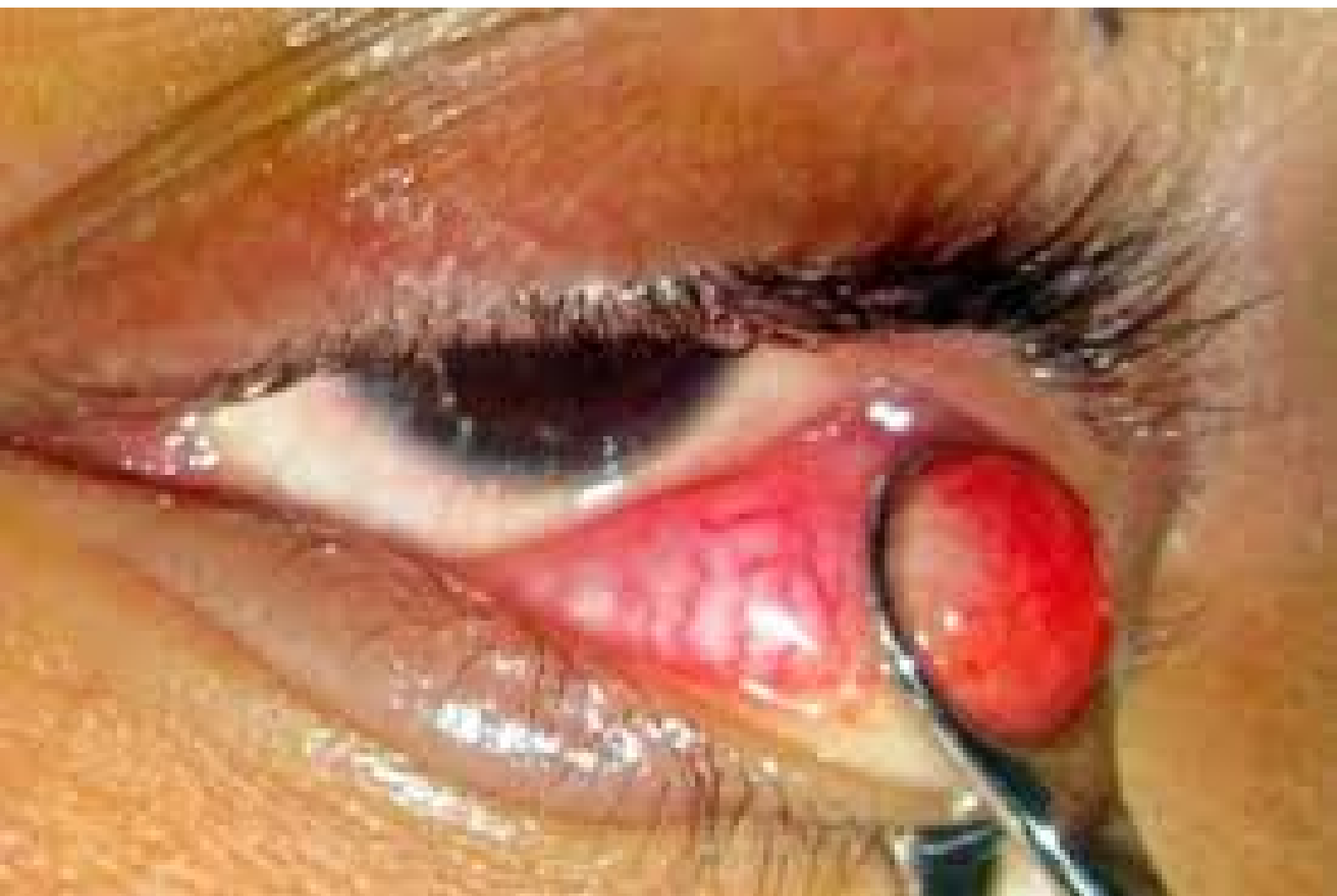




NORMAL EYE

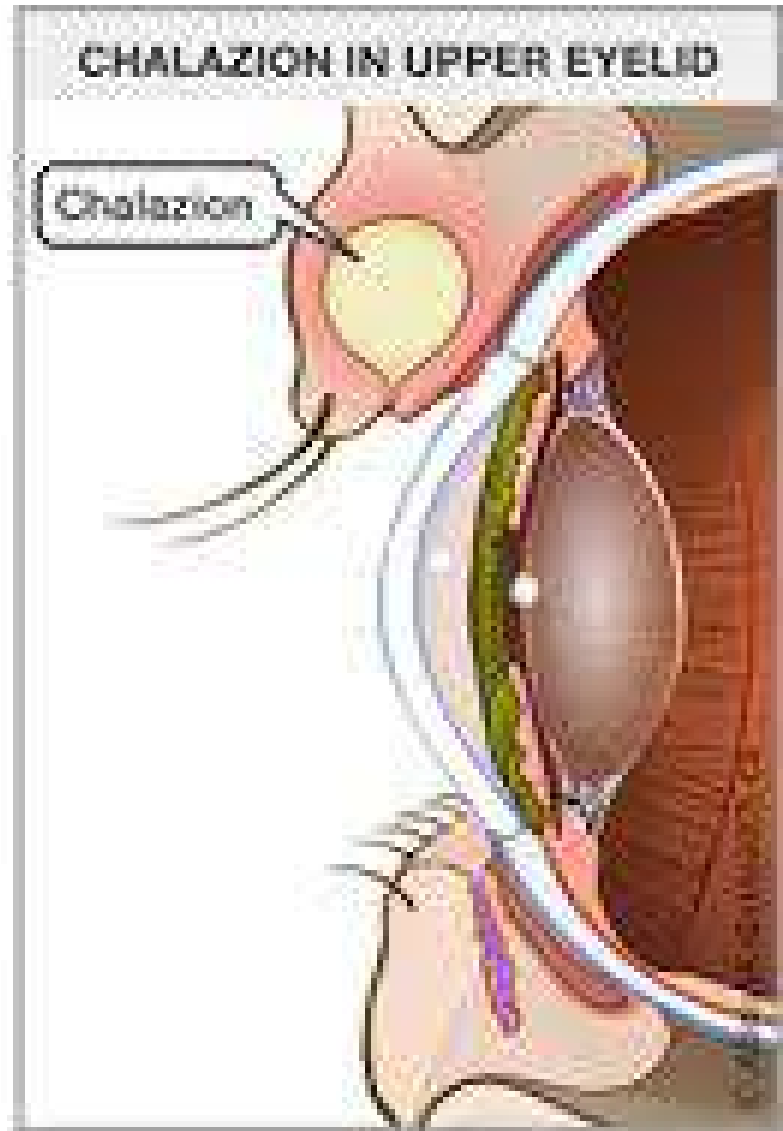
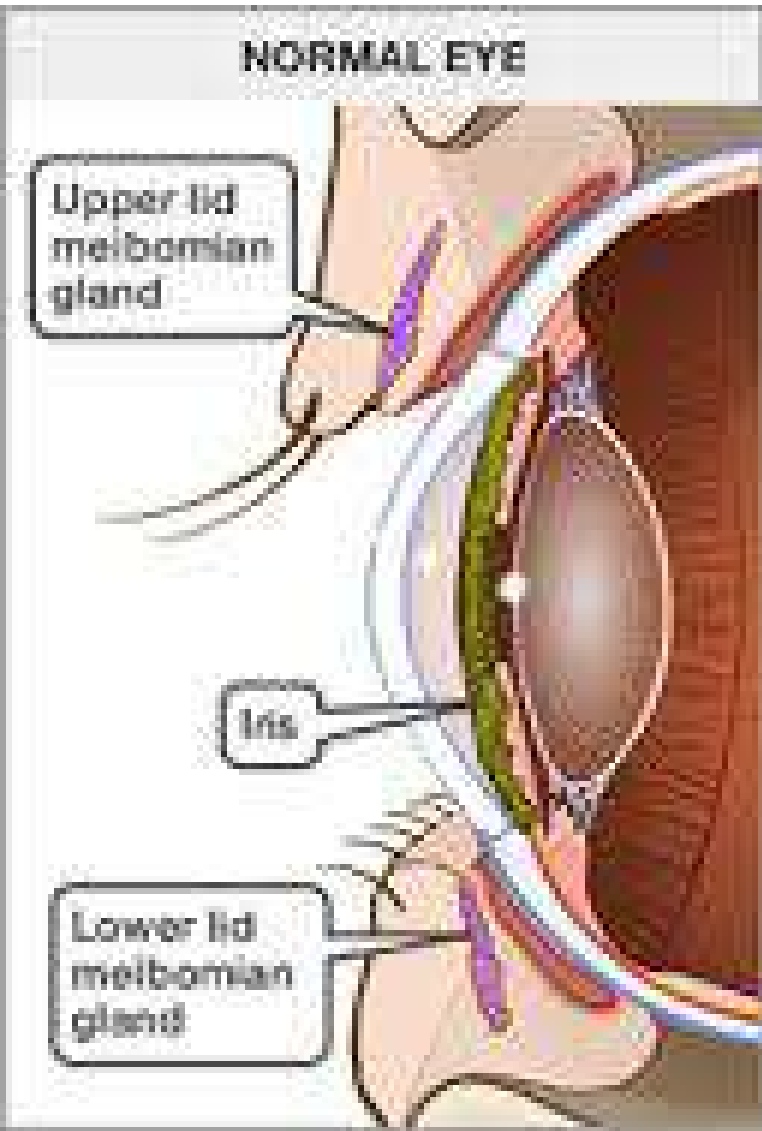
Upper lid
meibomian
gland

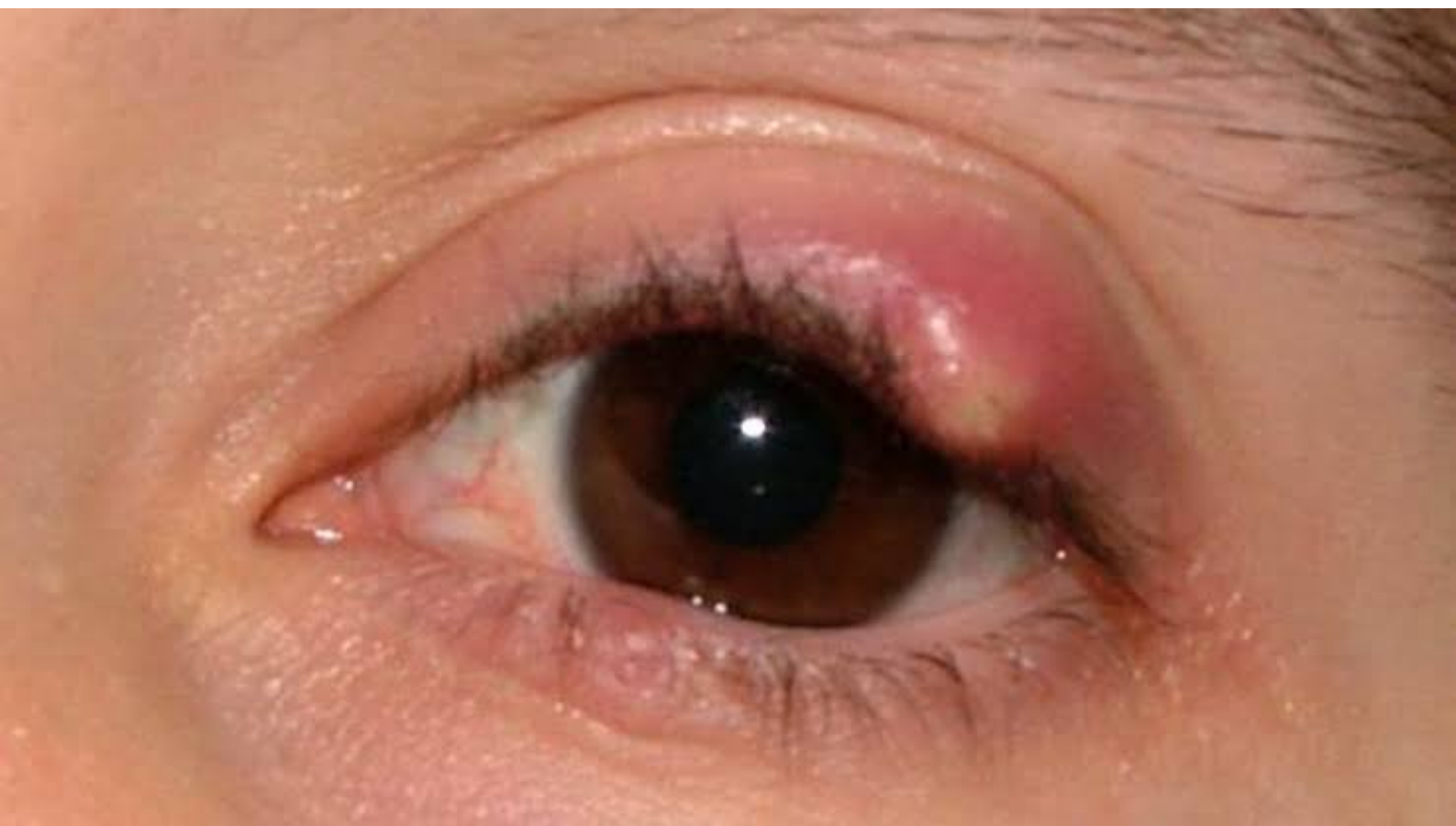Iris

Lower lid
meibomian
gland

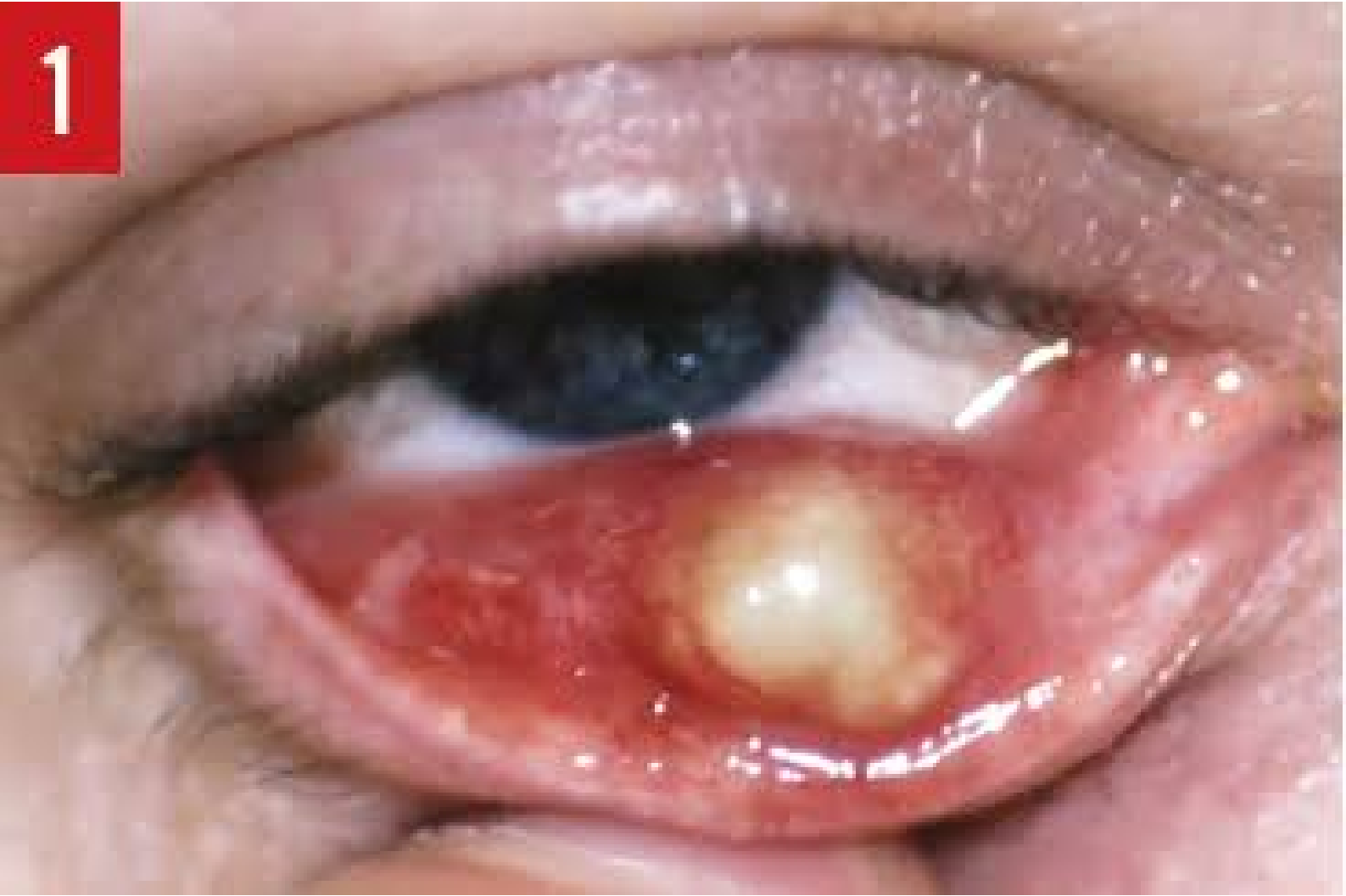CHALAZION IN UPPER EYELID

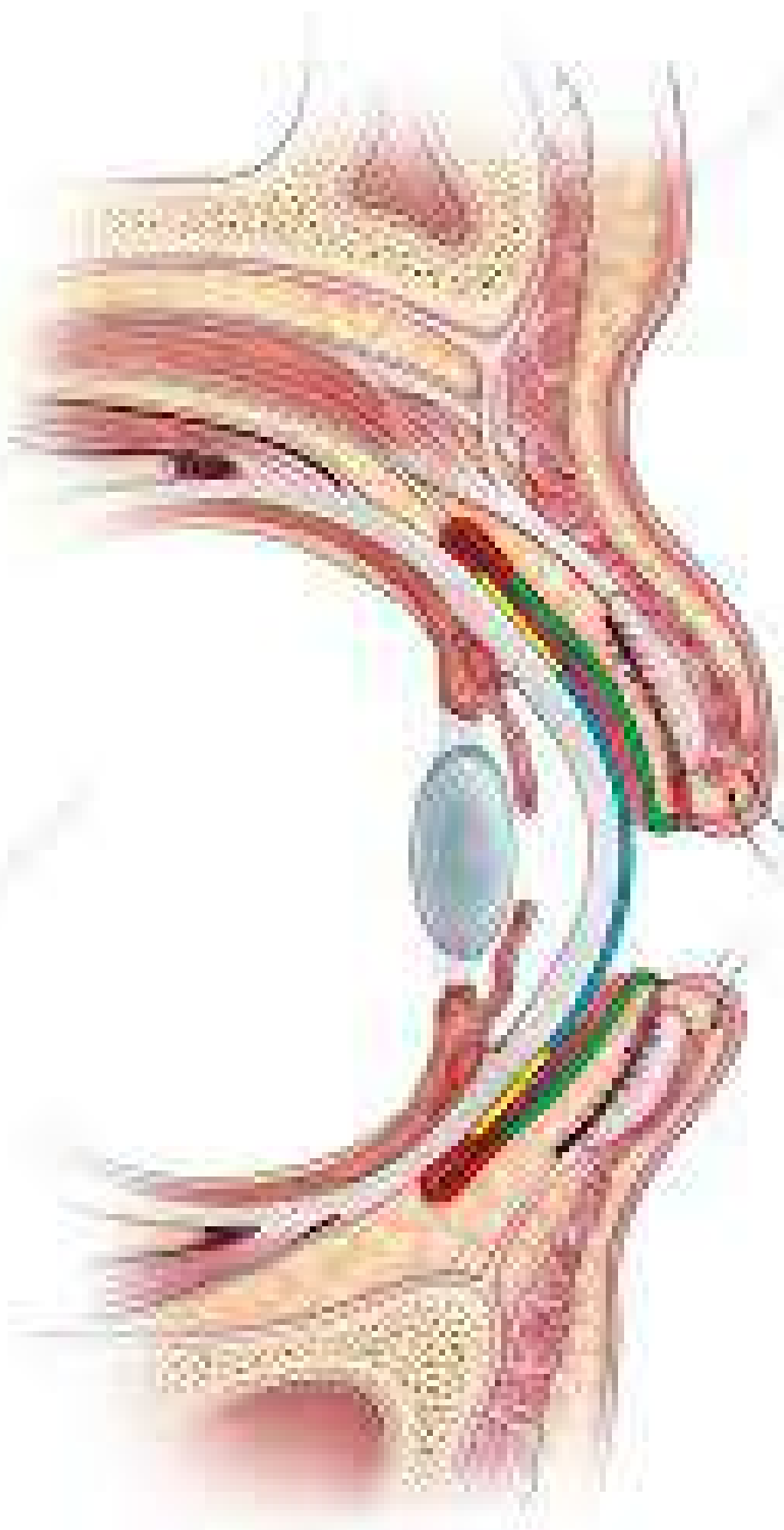
Chalazion





1





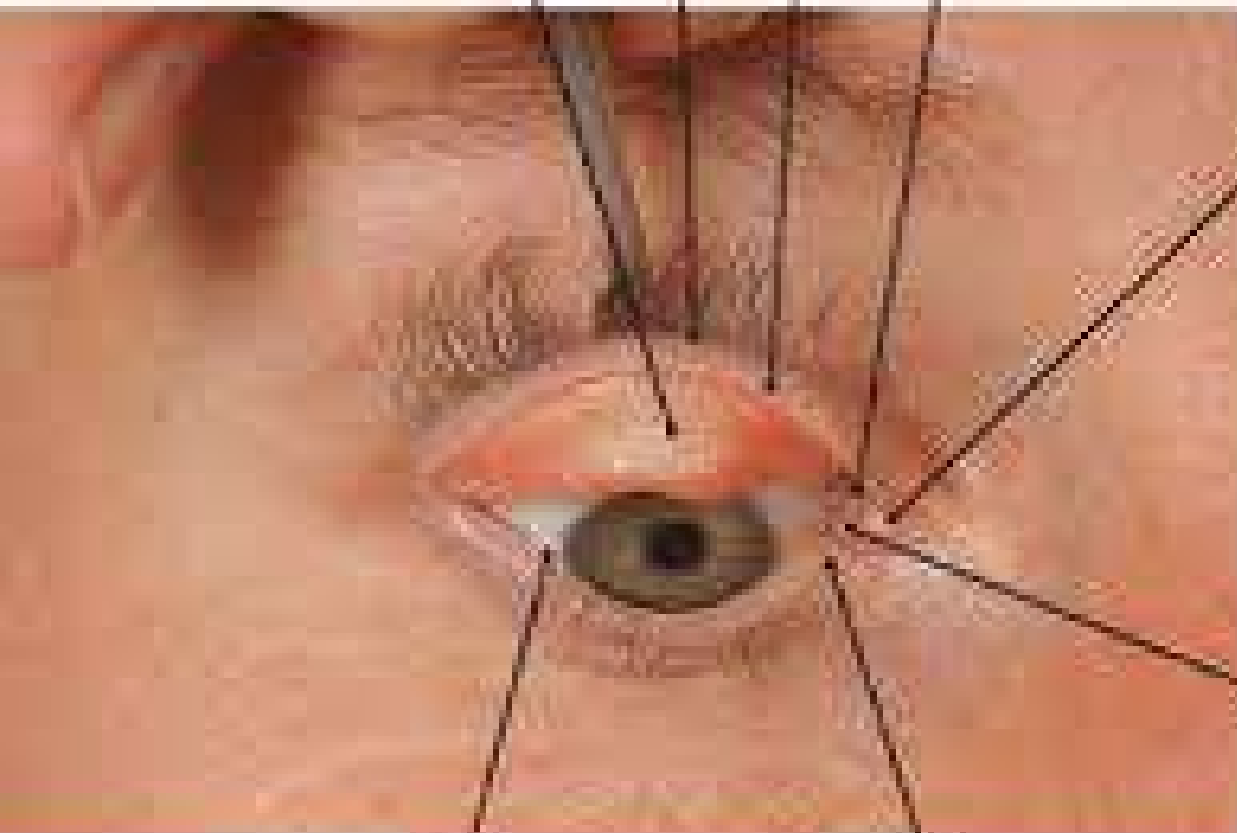
- Bulbar conjunctiva
- Conjunctival fornix
- Palpebral conjunctiva
- Surface of the cornea

Anterior palpebral margin

Posterior palpebral margin

Palpebral
conjunctiva

Lacrimal punctum;
(superior) lacrimal papilla

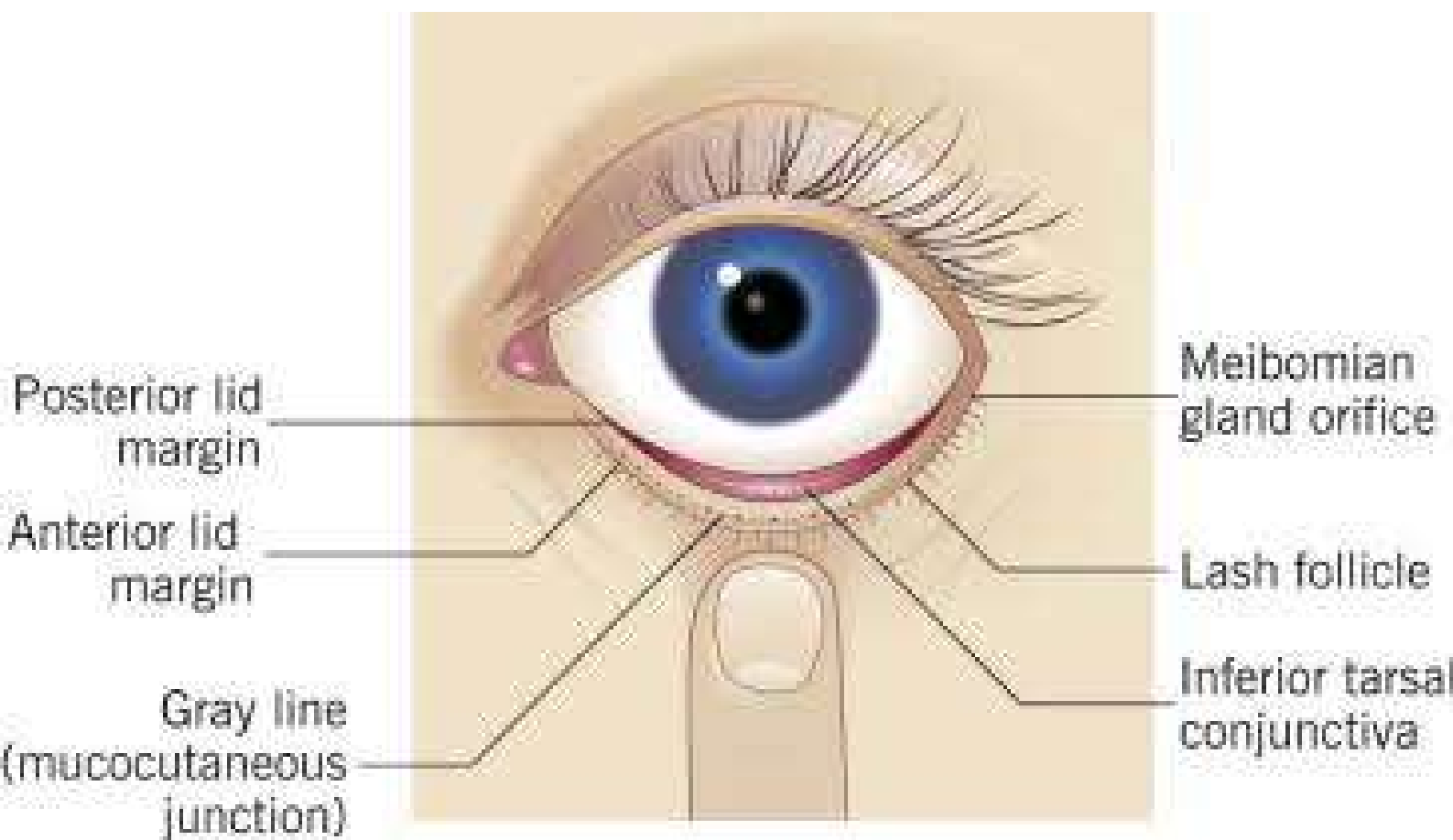


Lacrimal
caruncle

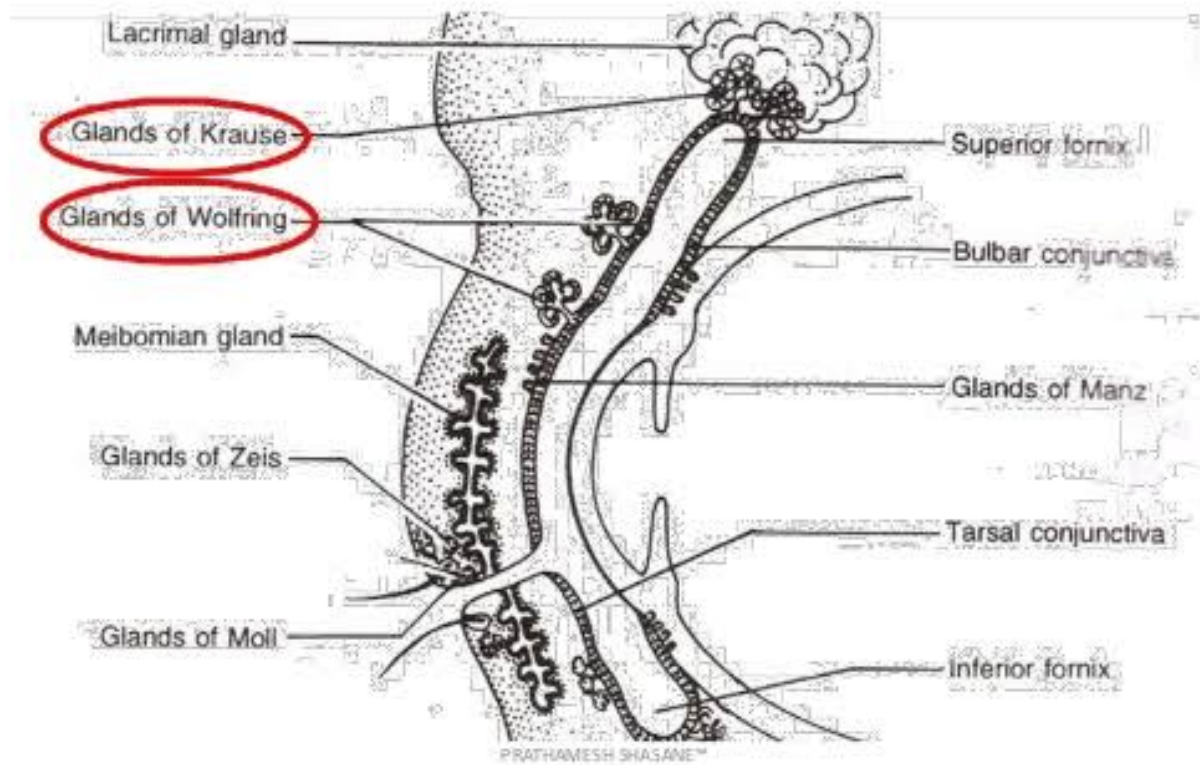
Semi-lunar
fold of
conjunctiva

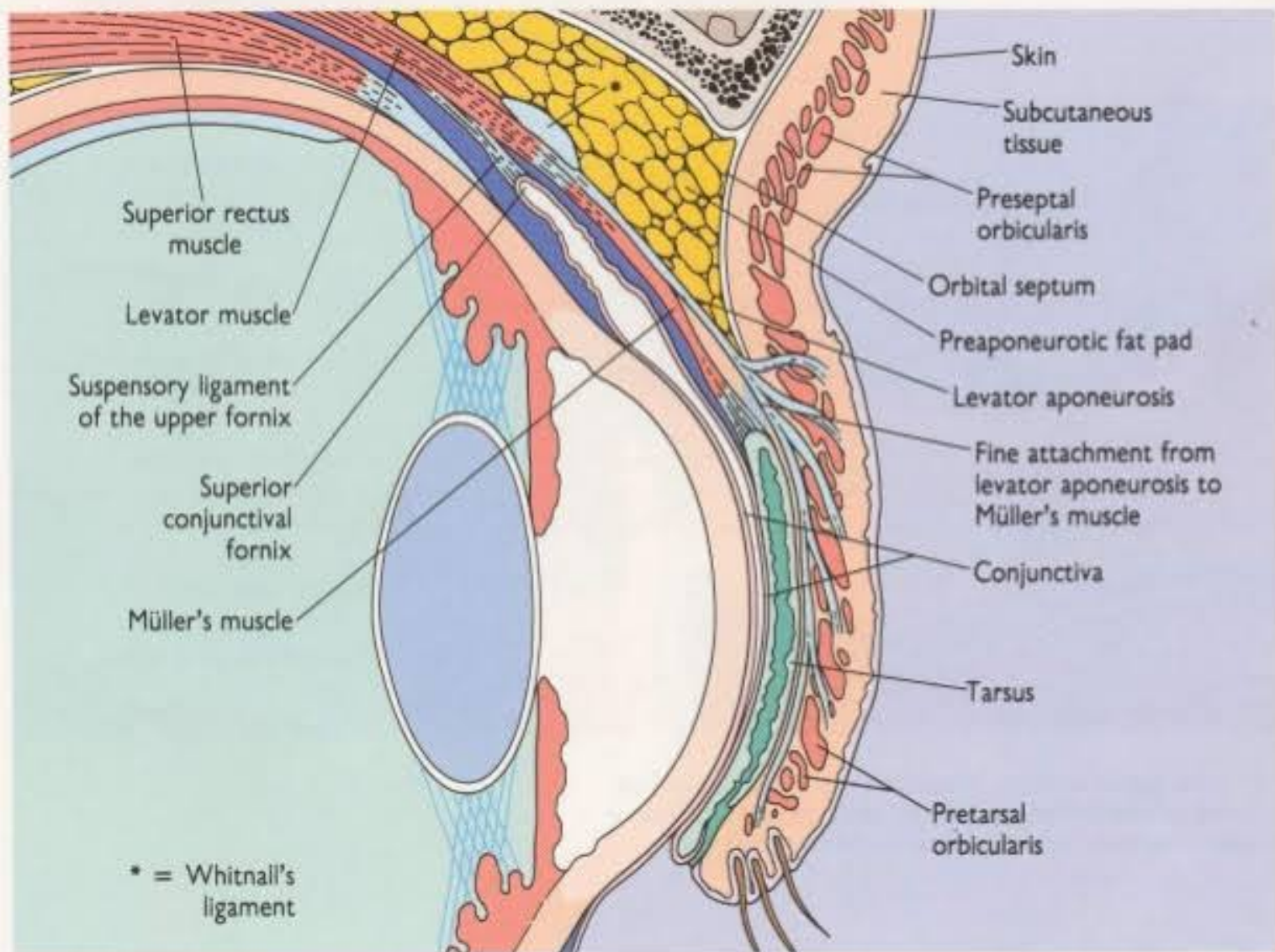
Lacus lacrimalis

Lacrimal punctum;
(inferior) lacrimal papilla



ACCESORY LACRIMAL GLANDS:





Parts Of Conjunctiva

